



ORIGINAL ARTICLE

Determining the Changes in Value of Segmental Longitudinal Strain and Global Longitudinal Strain in Discriminating Left Anterior Descending Artery Involvement

Mehran Radfar¹, Mohammad Moein Ashrafi², Mehrdad Sheikhvatan³, Afsaneh Sadeghian⁴, Hakimeh Sadeghian^{1*}

¹ Department of Cardiology, School of Medicine, Shariati Hospital Tehran University of Medical Sciences, Tehran, Iran

² Young Researchers and Elites Club, Faculty of Medicine, Islamic Azad University, Yazd Branch, Yazd, Iran

³ Pars Advanced and Minimally Invasive Medical Manners Research Center, Pars Hospital, Iran University of Medical Sciences, Tehran, Iran

⁴ Bahar Hospital, Shahrood University of Medical Science, Shahrood, Iran

* Corresponding Author: Hakimeh Sadeghian, Email: sadeghianhakimeh@yahoo.com

ARTICLE INFO

Article history

Received: Aug 28, 2019

Accepted: Aug 31, 2019

Published: Nov 11, 2019

Volume: 4

Issue: 3

Conflicts of interest: None

Funding: None

Key words

Segmental Longitudinal Strain (SLS),

Global Longitudinal Strain (GLS),

Coronary Artery Disease (CAD)

ABSTRACT

Introduction: The present study was conducted to determine the predictive role of the segmental longitudinal strain in predicting significant proximal left anterior descending stenosis in patients with coronary heart disease regarding specific cardiac segments.

Materials and Methods: This cross-sectional study was conducted on 90 consecutive patients who were candidates for coronary angiography and assessed using speckle-tracking echocardiography. All patients underwent echocardiography prior to coronary angiography and only patients with normal left ventricular ejection fraction were finally included. Besides, conventional echocardiography, all patients were subjected to speckle-tracking echocardiography determination, and the images were assessed in standard 3C, 2C, 4C views.

Results: 45 patients with significant proximal left anterior descending stenosis found from the coronary angiography report and 45 patients with had normal coronary arteries. Based on the surface area under the receiver operating characteristic curve analysis, the highest diagnostic ability to distinguish between left anterior descending involvement from normal coronary state was related to the segmental longitudinal strain of the septal basal segments (AUC = 0.962), antero-septal apical (AUC = 0.942) and septal mid portion (AUC = 0.941). For global longitudinal strain it was -20.45 (100% sensitivity, 95.5% specificity) regarding the global longitudinal strain diagnostic value in the prediction of proximal significant left anterior descending stenosis.

Conclusion: The measurement of segmental longitudinal strain in LAD segments and global longitudinal strain can predict proximal left anterior descending stenosis with high sensitivity and specificity.

INTRODUCTION

In recent years, a significant number of patients with typical chest pain diagnosed with low-risk acute coronary syndrome (ACS) but with no evidence of an increase in cardiac ischemic biomarkers have exploded (1-3). Besides, approximately one-third of patients who are candidates for coronary angiography also lack coronary artery stenosis in coronary angiography (4), which affects the cost burden of the disease and procedural complications. Exercise is a good test to identify

patients necessary for angiography, but this is limited in patients with persistent coronary heart disease (5). Hence, for these patients, computed tomography (CT) angiography will be a suitable non-invasive alternative for assessing the coronary artery anatomy. CT angiography is a useful method for ruling out patients with suspected ACS or other causes of chest pain, but due to a high level of radiation used in this method, it cannot be used for all patients. Therefore, it is necessary to use other non-invasive and especially inexpensive and accessible methods to determine patients for angiog-

patients necessary for angiography, but this is limited in patients with persistent coronary heart disease (5). Hence, for these patients, computed tomography (CT) angiography will be a suitable non-invasive alternative for assessing the coronary artery anatomy. CT angiography is a useful method for ruling out patients with suspected ACS or other causes of chest pain, but due to a high level of radiation used in this method, it cannot be used for all patients. Therefore, it is necessary to use other non-invasive and especially inexpensive and accessible methods to determine patients for angiography (6).

Evaluation and measurement of left ventricular deformation have widely been used to assess the left ventricular strain and strain rate using speckle tracking echocardiography (STE). Due to the homogeneous expansion of strain and strain rates in the myocardium, tracking even small changes in each of the above indicators may show myocardial dysfunction. Although STE is primarily used to assess and diagnose diseases that affect the myocardial functional status, it can also be used directly for the diagnosis or severity of ischemic heart disease. There is a significant relationship between subclinical left ventricular systolic dysfunction and coronary artery disease in the heart. Therefore, it can be predicted that the longitudinal strain and a strain rate of the left ventricle can be disturbed even after coronary artery stenosis in the normokinetic segments (7). Sometimes, even in patients with a normal electrocardiogram, strain, and strain rate disturbances in anterior segment showed a significant involvement in the left anterior descending (LAD) artery (8).

The evaluation of the longitudinal left ventricular strain with high precision and sensitivity can predict the severity of coronary artery disease and also determine the infarct size in patients with acute coronary syndrome. The present study aimed to assess the value of segmental and global longitudinal strain in patients with significant proximal LAD stenosis as compared to normal coronaries.

MATERIALS AND METHODS

This cross-sectional study was carried out on 90 consecutive patients who were candidates for coronary angiography and assessed using STE. The exclusion criteria were 1) moderate to severe valvular lesions, 2) conduction defects in the ECG, 3) pacemaker implantation, 4) atrial and/or ventricular continuous arrhythmias, 5) congenital heart disease, 6) history of previous heart surgery, or 7) needing emergency angiography, 8) hemodynamic instability, and 9) patients with no informed consent. The indication for coronary angiography in these patients were chest pain and positive non-invasive tests such as myocardial perfusion imaging (MPI) or Exercise Tolerance Test (ETT). All patients underwent echocardiography before coronary angiography and only patients with normal LVEF ($LVEF \geq 50\%$) were finally included. Patients who had coronary angiography with significant proximal LAD stenosis (over 70% of stenosis)

were considered as the case group and those with no coronary artery disease or stenosis of less than 50% were selected as a control group. Besides, conventional echocardiography, all patients were subjected to determine STE, and the images were analyzed with standard 3C, 2C, 4C views. In each view, three successive cardiac cycles were assessed. In the study endpoint, the patients with normal and proximal LAD stenosis was initially compared to segmental longitudinal strain (SLS) and global longitudinal strain (GLS) and the value for the SLS and GLS levels in discriminating LAD from normal coronary disorder was determined.

Descriptive analysis was used to describe the data, including mean \pm standard deviation (SD) for quantitative variables and frequency (percentage) for categorical variables. Chi-square test, t-test, and Mann-Whitney U test were used to compare variables. The ROC curve analysis was used to assess the best cutoff value and the sensitivity and specificity of SLS and GLS to predict LAD involvement. For the statistical analysis, the statistical software IBM SPSS Statistics for Windows version 22.0 (IBM Corp. Released 2013, Armonk, New York) was used. P-values < 0.05 were considered statistically significant.

RESULTS

In this study, 45 patients with proximal LAD stenosis found from the coronary angiography report and 45 patients with normal coronary arteries (both groups with normal LVEF) were included. All parameters of SLS and GLS were compared and categorized into two groups. Comparison of SLS parameters in all cardiac segments in both groups with and without proximal LAD stenosis showed a significant reduction in SLS in the LAD group compared to the normal coronary group in the following segments (see Table 1): Septal basal, Septal mid-portion, Septal apical, Lateral basal, Lateral mid-portion, Lateral apical, Apex in apical 4 chambers, Anterior basal, Anterior mid-portion and apical, Inferior basal, Inferior mid-portion and apical, Anteroseptal basal, Anteroseptal mid-portion, Anteroseptal apical, Posterior basal, Posterior mid-portion, and Posterior apical. The comparison of global longitudinal strain between the two groups also indicated a significant change in global GLS among those with LAD involved (Table 1). Based on the surface area under the ROC curve analysis and among all the SLSs of different segments, the highest diagnostic ability to distinguish between proximal LAD stenosis among normal coronary state was related to the SLS of the septal basal segments (AUC = 0.962), Posterior apical (AUC = 0.948), anteroseptal apical (AUC = 0.942) and septal mid-portion (AUC = 0.941) (Table 2). The best cut off point for septal basal was -19.5 (100% sensitivity, 91.1%), for posterior apical was -21.5 (100% sensitivity, 91.1% specificity), for apical anteroseptal was -0.25 (100% sensitivity, 91.1% specificity), for septal mid-portion was -0.61 (100% sensitivity, 88.9%). Regarding the GLS diagnostic value in the prediction of proximal LAD stenosis, the area under the

Table 1. Changes in segmental longitudinal strain and global longitudinal strain parameters in Proximal LAD stenosis and normal subjects

Item	With Proximal LAD Stenosis	Without LAD Stenosis	P-value
Septal basal	-14.16 ± 4.56	-24.62 ± 6.00	< 0.001
Septal mid portion	-11.04 ± 5.24	-23.76 ± 6.67	< 0.001
Septal apical	-25.07 ± 6.91	-35.00 ± 7.92	< 0.001
Lateral basal	-20.18 ± 21.91	-25.08 ± 7.39	0.106
Lateral mid portion	-15.76 ± 6.16	-27.42 ± 6.18	< 0.001
Lateral apical	-19.76 ± 5.65	-25.58 ± 8.58	< 0.001
Apex in apical 4 chambers	-22.36 ± 5.66	-27.58 ± 6.03	< 0.001
Anterior basal	-14.07 ± 6.50	21.76 ± 5.35	< 0.001
Anterior mid portion	-18.82 ± 3.81	-16.22 ± 3.08	0.500
Anterior apical	-17.91 ± 5.89	-18.49 ± 2.42	0.544
Inferior basal	-13.82 ± 5.26	-21.71 ± 8.38	< 0.001
Inferior mid portion	-11.44 ± 4.66	-21.29 ± 4.52	< 0.001
Inferior apical	-21.47 ± 7.75	-22.73 ± 5.00	0.359
Apex in apical 2 chambers	-19.87 ± 6.47	-19.08 ± 3.66	0.481
Anteroseptal basal	-10.53 ± 5.09	-17.00 ± 7.10	< 0.001
Anteroseptal mid portion	-11.87 ± 4.89	-15.82 ± 11.75	0.040
Anteroseptal apical	-15.00 ± 7.20	-27.38 ± 1.23	< 0.001
Posterior basal	-12.11 ± 5.83	-19.11 ± 3.45	< 0.001
Posterior midportion	-12.47 ± 6.69	-21.69 ± 2.91	< 0.001
Posterior apical	-14.31 ± 5.93	-23.62 ± 1.23	< 0.001
Apex in apical 3 chambers	-21.93 ± 5.20	-24.67 ± 1.91	0.601
GLSA4C	-17.21 ± 4.53	-26.67 ± 6.67	< 0.001
GLSA2C	-15.44 ± 5.40	-19.61 ± 4.04	< 0.001
GLSA3C	-13.33 ± 4.99	-22.76 ± 2.25	< 0.001
Global GLS	-14.80 ± 3.49	-22.88 ± 1.15	< 0.001

(Abbreviations; LAD: left anterior descending, GLS: global longitudinal strain)

Table 2. Determining the value of segmental longitudinal strain and global longitudinal strain parameters in predicting proximal LAD stenosis from the area under ROC

Item	Area under ROC	Cutoff	Sensitivity	Specificity
Septal basal	0.962	-19.5	100	91.1
Septal mid portion	0.941	-18.0	100	88.9
Septal apical	0.812	-22.5	100	35.6
Lateral basal	0.692	-23.5	62.2	77.8
Apex in apical 4 chambers	0.698	-23.5	62.2	62.2

Anterior basal	0.711	-14.5	66.7	60.0
Anterior mid portion	0.644	-12.5	100	51.1
Anterior apical	0.498	-17.5	66.7	42.2
Inferior basal	0.535	-18.5	66.7	37.8
Apex in apical 2 chambers	0.461	-20.5	66.7	57.8
Anteroseptal basal	0.702	-11.0	100	46.7
Anteroseptal mid portion	0.539	-12.5	71.1	48.9
Anteroseptal apical	0.942	-25.0	100	91.1
Posterior apical	0.948	-21.5	100	91.1
Apex in apical 3 chambers	0.915	-21.5	100	80.0
GLS4	0.924	-21.7	100	86.4
GLS2	0.756	-21.4	66.7	86.4
GLS3	0.937	-19.15	100	90.9
Global GLS	0.983	-20.45	100	95.5

(Abbreviations; LAD: left anterior descending, ROC: receiver operating characteristic curve)

ROC curve was 0.924, 0.756, 0.9073, and 0.983 for GLS4, GLS2, GLS3, and Global GLS, respectively. The best cutoff point for GLS4 was -21.7 (100% sensitivity, 86.4% specificity), for GLS2 was -21.4 (66.7% sensitivity, 86.4% specificity), for GLS3 was -19.15% (100% sensitivity, 90.9%), and finally for Global GLS was -20.45 (100% sensitivity, 95.5% specificity). (see Figures 1-6)

Comparison of cardiac dimensions including left atrial (LA), interventricular septum diameter (IVSD), left

ventricular dimension in diastole (LVDD), left ventricular systolic dimension (LVSD), posterior wall diameter (PWD), right ventricle diameter (RVD), and tricuspid annular plane systolic excursion (TAPSE) showed no significant difference between the two groups with and without LAD involvement in any of these indices (see Table 3).

Table 3. Comparison of echocardiography data in proximal LAD stenosis and normal subjects:

Item	With Proximal LAD involvement	Without LAD involvement	P-value
LA	19.76 ± 5.65	19.11 ± 4.96	0.879
IVSD	14.00 ± 10.57	14.12 ± 10.98	0.956
LVDD	41.98 ± 15.35	39.36 ± 12.55	0.224
RVD	27.36 ± 5.36	26.12 ± 5.05	0.556
PWD	11.95 ± 5.21	11.36 ± 5.50	0.456
LVSD	26.64 ± 11.10	25.25 ± 9.18	0.324
TAPSE	21.44 ± 2.96	21.12 ± 1.86	0.756
LVEF	54.78 ± 3.78	54.22 ± 3.22	0.871
PAPs	26.87 ± 6.19	25.95 ± 5.28	0.356

(Abbreviations; LAD: left anterior descending, LA: left atrial, IVSD: interventricular septum diameter, LVDD: left ventricular dimension in diastole, RVD: right ventricle diameter, PWD: Posterior wall diameter, LVSD: left ventricular systolic dimension, TAPSE: tricuspid annular plane systolic excursion, LVEF: left ventricular ejection fraction, PAPs: Systolic pulmonary artery pressure)

Fig 1. Septal basal segments

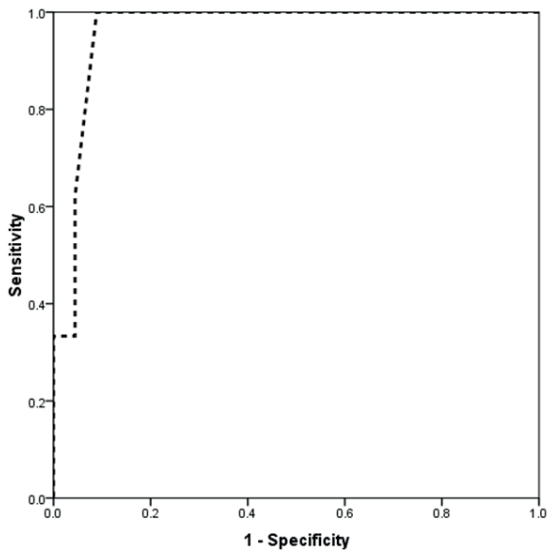


Fig 2. Posterior apical

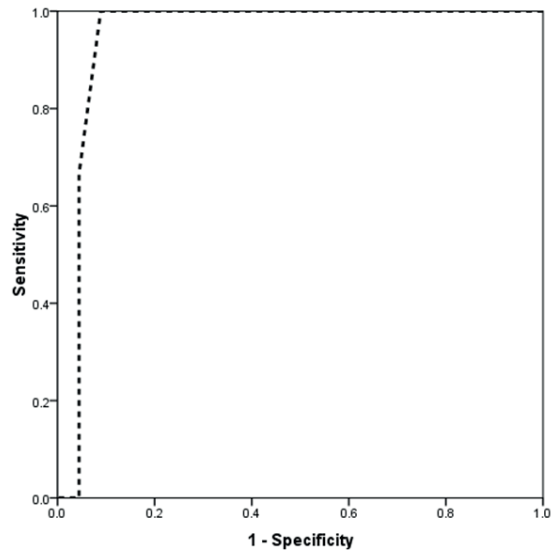


Fig 3. Anteroseptal apical

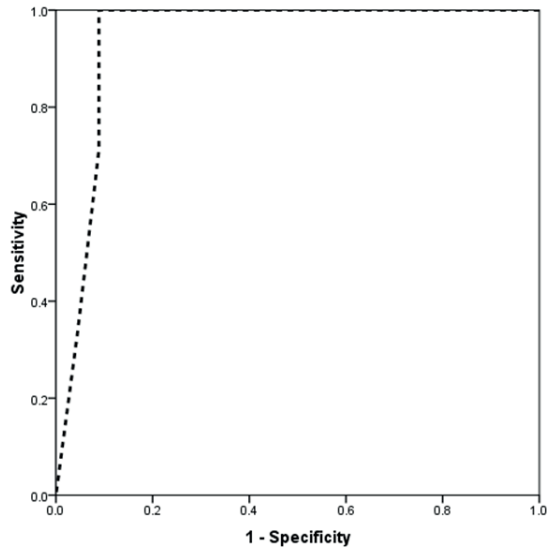


Fig 4. Septal mid portion

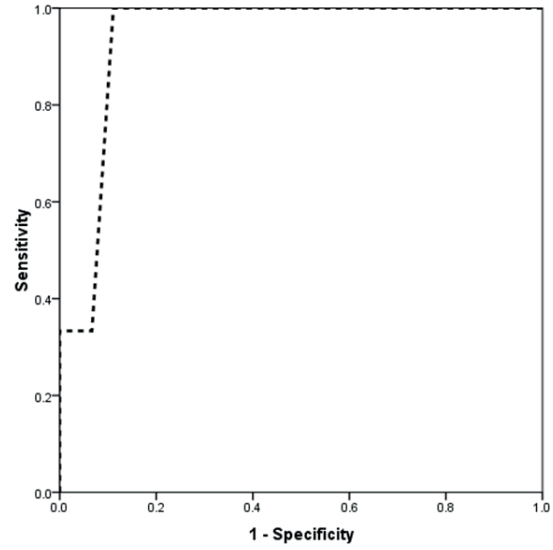
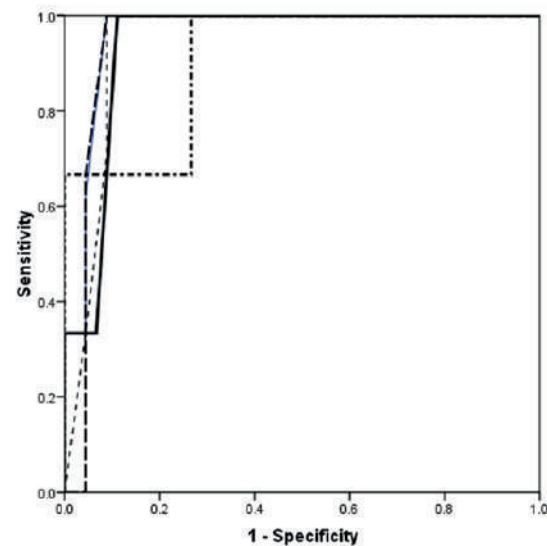


Fig 5. All Segments



Source of the Curve
 — sb
 - - pa
 — smp
 - - asa
 - - - - imp

DISCUSSION

According to the results of this study, 9 out of 12 LAD segments showed reduced SLS in the significant proximal LAD stenosis. GLSAC4, GLSA2C and GLSA3C and global GLS also showed a significant decline. This finding allows providing a precise and predictable prediction of coronary artery disease, especially proximal LAD stenosis with non-invasive imaging.

In previous studies, the diagnostic role of SLS and GLS in predicting ischemic heart disease has been demonstrated. Liang et al. showed that the SRs and SRE values in the ischemic group were significantly reduced compared to the normal coronary group. The reduction in both parameters with a sensitivity of 93% and specificity of 93% probability could predict ischemic involvement in the heart (9), which

was fully consistent with the present study. Tsai et al. examined that the amount of GLS in patients with CAD was significantly reduced. Using the ROC curve analysis, the area under the curve for GLS in the CAD prediction was 0.813 and the number of segments involved was 0.851, showing the ability of both parameters for CAD prediction (10). Choi et al. reported that SLS could show a significant decrease in CAD in patients. The surface under the ROC curve showed that the amount of peak SLS could differentiate patients with severe CAD from the normal conditions (AUC = 0.830). The cutoff point of 17.9% for SLS could differentiate CAD with a sensitivity of 79% and a specificity of 79% (11). Nucifora et al. showed that GLS was a strong predictor of the presence of CAD. GLS values higher than 17.4 with sensitivity and specificity of 83% and 77% could predict CAD and diastolic dysfunction (12). In different studies, the different cutoff points of the SLS and GLS parameters were obtained to predict the presence and severity of coronary artery disease, depending to various factors such as the evaluation of SLS and GLS parameters based on expert experiences, study design and study power, how the definition of the severity of coronary artery disease, and the cardiac segments. In the present study, the target population included only the group of a single LAD involvement. Due to the high blood flow of the myocardium by the LAD epicardial vein, the results can lead to a prediction of extensive ischemia following LAD involvement with high sensitivity and specificity. By considering GLS and SLS parameters simultaneously; it is possible to predict LAD involvement with much higher accuracy.

In our previous study, mean ST and SR showed a significant reduction in the stenotic LAD group compared to non-stenotic group ($P < 0.001$). A segment-by-segment comparison revealed a reduction of ST in 4/9 (two apical and two anteroseptal) and SR in 5/9 (three apical, septal, and anteroseptal midportion) in the stenotic group ($P < 0.05$). Both ST and SR showed a significant reduction in three segments: anterior-apical, lateral-apical, and anteroseptal-midportion. When both ST and SR decreased in one segment, specificity and sensitivity for the diagnosis of proximal LAD stenosis was more than 80% and 55%, respectively, by Roc analysis (40).

CONCLUSION

As a conclusion, the evaluation of SLS in various LAD segments and global GLS can predict significant proximal LAD stenosis with high sensitivity and specificity. The reduction of each of these parameters of STE can be reliable and sensitive variables along with other clinical and laboratory indicators to predict proximal significant LAD stenosis.

ACNOWLEDGMENTS (Funding source)

We are thankful of Tehran Heart Center employees for their kindness and also special thanks to the patients for their

contribution in this study. The authors have no funding to report.

AUTHOR CONTRIBUTIONS

Study concept and design: H.S.; analysis and interpretation of data: M.S., and M.R.; drafting of the manuscript: M.A.; critical revision of the manuscript for important intellectual content: M.R., H.S., and A.S.; statistical analysis: M.R., and M.S.

CONFLICT OF INTERESTS

The authors declare that there are no conflicts of interest in this study.

ETHICAL STANDARDS

All procedures performed in studies involving human participants were in accordance with the ethical standards of the Ethics Committee of Tehran University of Medical Sciences (TUMS).

REFERENCES

1. Aune E, Hjelmestaeth J, Fox KA, Endresen K, Otterstad JE. High mortality rate in conservatively managed patients with acute coronary syndrome. *Scand Cardiovasc J*. 2006;40:137–44.
2. Narallah N, Steiner H, Hasin Y. The challenge of chest pain in the emergency room: now and in the future. *Eur Heart J*. 2011;32:656.
3. Ruddox V, Mathisen M, Otterstad JE. Prevalence and prognosis of non-specific chest pain among patients hospitalized for suspected acute coronary syndrome—a systematic literature search. *BMC Medicine*. 2012;10:58.
4. Damman P, van Geloven N, Walentin L, Lagerqvist B, Fox CA, Clayton T, et al. Timing of angiography with a routine invasive strategy and long-term outcomes in non-ST segment evaluation acute coronary syndrome: a collaborative analysis of individual patient data from the FRISC II (Fragmin an Fast Revascularization During Instability in Coronary Artery Disease), ICTUS (Invasive versus conservative Treatment in Unstable Coronary Syndormes), and RITA-3 (Intervention vs Conservative treatment Strategy in Patients With Unstable Angina or Non-ST elevation Myocardial Infarction) Trial. *J Am Coll Cardiol Intv*. 2012;5:191–9.
5. Montalescot G, Sechtem U, Achenbach S, Andreotti F, Arden C, Budaj A, et al. ESC guidelines on the management of stable coronary artery disease. *European Heart Journal*. 2013;2013(34):2949–3003.
6. Hamm CW, Bassand JP, Agewall S, Bax J, Boersma E, Bueno H, et al. ESC Guidelines for the management of acute coronary syndromes in patients presenting without persistent ST-segment elevation: The Task Force for the manage-

ment of acute coronary syndromen (ACS) in patients presenting without persistent ST-segment elevation of the European Society of Cardiology. *European Heart Journal*. 2011;32:2999–3054.

7. Feigenbaum H, Mastouri R, Sawada S. A practical approach to using strain echocardiography to evaluate the left ventricle. *Circ J*. 2012;76:1550–5.

8. Jamal F, Sutherland GR, Weidemann F, D'hooge J, Bijmens B, Derumeaux G. Can changes in systolic longitudinal deformation quantify regional myocardial function after an acute infarction? An ultrasonic strain rate and strain study. *J Am Soc Echocardiogr*. 2002;15:723–730.

36. Liang HY1, Cauduro S, Pellikka P, Wang J, Urheim S, Yang EH, Rihal C, Belohlavek M, Khandheria B, Miller FA, Abraham TP. Usefulness of two-dimensional speckle strain for evaluation of leftventricular diastolic deformation in patients with coronary artery disease. *Am J Cardiol*. 2006 Dec 15;98(12):1581-6. Epub 2006 Oct 25.

37. Tsai WC1, Liu YW, Huang YY, Lin CC, Lee CH, Tsai LM. Diagnostic value of segmental longitudinal strain by automatedfunction imaging in coronary artery disease without left ventricular dysfunction. *J Am Soc Echocardiogr*. 2010 Nov;23(11):1183-9. doi: 10.1016/j.echo.2010.08.011. Epub 2010 Sep 15.

38. Choi JO1, Cho SW, Song YB, Cho SJ, Song BG, Lee SC, Park SW. Longitudinal 2D strain at rest predicts the presence of left main and three vessel coronary artery disease in patients without regional wallmotion abnormality. *Eur J Echocardiogr*. 2009 Jul;10(5):695-701. doi: 10.1093/ejecho-card/jep041. Epub 2009 Apr 28.

39. Nucifora G1, Schuijf JD, Delgado V, Bertini M, Scholte AJ, Ng AC, van Werkhoven JM, Jukema JW, Holman ER, van der Wall EE, Bax JJ. Incremental value of subclinical left ventricular systolic dysfunctionfor the identification of patients with obstructive coronary arterydisease. *Am Heart J*. 2010 Jan;159(1):148-57. doi: 10.1016/j.ahj.2009.10.030.

40. Zavar R, Sadeghian H, Lotfi-Tokaldany M, Ashrafi MM, Fathollahi MS, Sadeghian A. Longitudinal Tissue Velocity and Deformation Imaging in Patients with Significant Stenosis of Left Anterior Descending Artery. *IMMINV*. 2019 Feb 19;4(1). doi:10.24200/imminv.v2i4.197.