



CASE REPORT

**Difficult Airway Management with a King Vision Video Laryngoscope in an Anticipated Patient and an Unexpected Patient: Two Scenarios, One Device**

Eugenio Martinez-Hurtado<sup>1\*</sup>, Miriam Sanchez-Merchante<sup>2</sup>, Javier Ripolles-Melchor<sup>3</sup>

<sup>1</sup>Anesthesia and Critical Care Department, Infanta Leonor University Hospital, Madrid, Spain

<sup>2</sup>Anesthesia and Critical Care Department, Alcorcon Foundation University Hospital, Spain

<sup>3</sup>Anesthesia and Critical Care Department, Infanta Leonor University Hospital, Madrid, Spain

\*Correspondence Author: Eugenio Martinez-Hurtado, E-mail: [emartinez@anestesiari.org](mailto:emartinez@anestesiari.org)

ARTICLE INFO

Article history

Received: Aug 08, 2017

Accepted: Sep 09, 2017

Published: Feb 08, 2017

Volume: 3

Issue: 1

Conflicts of interest: None

Funding: None

Keywords

Airway Management

Laryngoscopy

Patient Safety,

Intubation

ABSTRACT

The King Vision Video Laryngoscope is a relatively new device that has been incorporated in our daily surgical practice, intensive care unit, and remote areas. It has become one of the main alternatives to the rescue of a failed intubation, a tool to manage patients with difficult intubation predictors, and the first choice in ventilate and not-intubate situations. **Case Presentation:** In this case report, we present the management of two difficult airway cases: one in an induced patient and the other in an anticipated patient, according to the Canadian Airway Focus Group difficult airway recommendations. **Conclusion:** The King Vision Video Laryngoscope is effective in most adult patients and can be used with a mouth opening of at least 13 mm. Even is an effective dispositive, it has yet to show results in the management both conventional airway both difficult airway in routine clinical practice.

INTRODUCTION

The King Vision Video Laryngoscope is a relatively new device that has been incorporated in our daily surgical practice, intensive care unit, and remote areas. It has become one of the main alternatives to the rescue of a failed intubation, a tool to manage patients with difficult intubation predictors, and the first choice in ventilate and not-intubate situations.

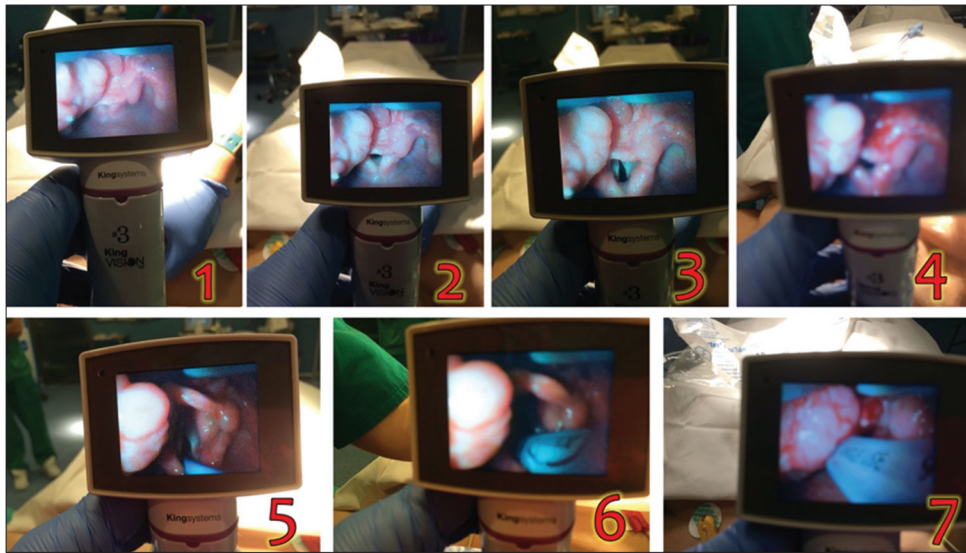
In this case report, we present the management of two difficult airway cases: one in an induced patient and the other in an anticipated patient, according to the Canadian Airway Focus Group difficult airway recommendations (1,2).

CASES

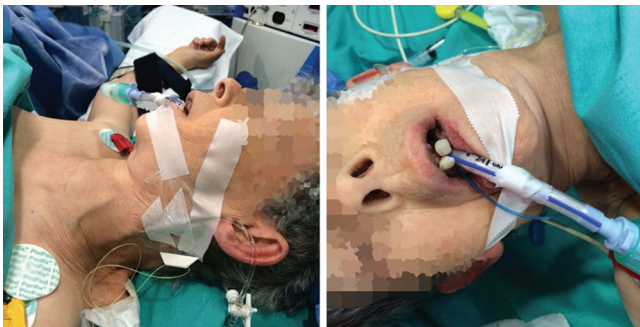The first patient was a 47-year-old woman with Barrett esophagus who was scheduled for elective surgery with Nissen fundoplication. Her body mass index (BMI) was 33.3 kg/m<sup>2</sup> (159 cm, 84.2 kg), Arne multivariate test was 3, Khan test was 1, and KIM test was 4.78. After induction, our first attempt was with a Macintosh direct laryngoscope.

We achieved an unexpected Cormack-Lehane 3e classification and identified a previously unknown glottic edema tumor that appeared to be a lymphoid. Our second attempt was with a King Vision channeled blade, and we achieved a Cormack-Lehane 2e classification. After this second attempt, we intubated with a Frova bougie introducer without problems (Image 1).

The second patient was a 56-year-old woman scheduled for elective surgery for restoration of intestinal transit after sigmoidectomy. Her BMI was 19.4 kg/m<sup>2</sup> (153 cm, 45.5 kg). It was her fourth surgery, and she had a history of a Cormack-Lehane 4 classification in two previous elective surgeries. During the second surgery, she was awake after induction and awake for fibrobronchoscopy intubation; during the third surgery, she was awake for intubation. Arne multivariate test was 24 and Khan test was 3 (Image 2). Our first attempt was with a King Vision channeled blade after optimal oxygenation by face mask, induction, and relaxation. Our second attempt was rescue with fibrobronchoscopy. We achieved a Cormack-Lehane 1 classification, and we intubated without problems.



**Image 1.** Unforeseen Difficult Airway in case one



**Image 2.** Predicted Difficult Airway management in case two

**DISCUSSION**

An increase in morbidity was reported after two direct laryngoscopy attempts during intubation (3,4). In addition, a 94% (5) and 99% (6,7) success rate was reported in rescue of intubation with video laryngoscopes when direct laryngoscopy failed.

The 4<sup>th</sup> National Audit Britannic Project (8) reported several cases of morbidity and mortality related to anticipated difficult airway, especially when rescue plans failed. It concluded that when a difficult airway is anticipated, intubation with the patient induced is justifiable only when there is a low risk of failed oxygenation and an immediate rescue plan is in place. Otherwise, awake fibrobronchoscopy intubation was recommended.

The Macintosh direct laryngoscope is still the gold standard (9), but it has a limited view of the larynx and a constricted field of vision of 15 degrees. Video laryngoscopes allow a panoramic view of the glottis independent of the line of sight, a field of vision over 60 degrees, no need for aligning the axes, and the achievement of a Cormack-Lehane classification of 1 or 2 in most cases. For these reasons, video laryngoscopes have become rescue alternatives in the event of a failed intubation or in the management of patients with difficult intubation predictors. They were introduced in the 2013 American Society of Anesthesiologists difficult airway algorithms as the first option in ventilate and not-intubate situations (10,11).

**CONCLUSION**

The King Vision Video Laryngoscope is effective in most adult patients and can be used with a mouth opening of at least 13 mm. Even is an effective dispositive, it has yet to show results in the management both conventional airway and difficult airway in routine clinical practice.

**REFERENCES**

1. Law JA, Broemling N, Cooper RM, Drolet P, Duggan LV, Griesdale DE, Hung OR, Jones PM, Kovacs G, Massey S, Morris IR, Mullen T, Murphy MF, Preston R, Naik VN, Scott J, Stacey S, Turkstra TP, Wong DT; Canadian Airway Focus Group. The difficult airway with recommendations for management--part 1--difficult tracheal intubation encountered in an unconscious/induced patient. *Can J Anaesth.* 2013 Nov;60(11):1089-118.
2. Law JA, Broemling N, Cooper RM, Drolet P, Duggan LV, Griesdale DE, Hung OR, Jones PM, Kovacs G, Massey S, Morris IR, Mullen T, Murphy MF, Preston R, Naik VN, Scott J, Stacey S, Turkstra TP, Wong DT; for the Canadian Airway Focus Group. The difficult airway with recommendations for management - Part 2 - The anticipated difficult airway. *Can J Anaesth.* 2013 Nov;60(11):1119-1138.
3. Mort TC: Emergency tracheal intubation: complications associated with repeated laryngoscopic attempts. *Anesth Analg* 2004, 99(2):607-613.
4. Mort TC et al. Emergency tracheal intubation: complications associated with repeated laryngoscopic attempts. *Anesth Analg* 2004;99:607-13. PMID:15271750.
5. Asai T et al. Use of pentax-AWS in 293 patients with difficult airways. *Anesthesiology* 2009; 110:898-904.
6. Aziz MF et al. Routine clinical practice effectiveness of the glidescope in difficult airway management: an analysis of 2004 intubations, complications and failures from two institutions. *Anesthesiology* 2011;114:34-41. PMID:21150569.
7. Apfelbaum JI et al. American Society of Anesthesiologist task force on management of the difficult airway. *Anesthesiology* 2013; 118:251-70.

- 
8. Cook T, Woodall N, Frerk C. 4<sup>th</sup> National Audit Project of the Royal College of Anaesthetists and the Difficult Airway Society. Major complications of airway management in the UK: results of the Fourth National Audit Project of the Royal College of Anaesthetists and the Difficult Airway Society. Part 1: anaesthesia. *Br J Anaesth*. 2011 May;106(5):617-31.
  9. Shiga T, Wajima Z, Inoue T, Sakamoto A: Predicting difficult intubation in apparently normal patients: a meta-analysis of bedside screening test performance. *Anesthesiology* 2005, 103 (2):429-437.
  10. Sakles JC., Mosier J., Chiu S. A Comparison of the C-MAC Video Laryngoscope to the Macintosh Direct Laryngoscope for Intubation in the Emergency Department. *Ann Emerg Med* 2012 May 4.
  11. Apfelbaum JL, Hagberg JA, Caplan RA, et al. American Society of Anesthesiologists. Task Force on Management of the Difficult Airway. Practice Guidelines for Management of the Difficult Airway. *Anesthesiology* 2013; 118:251–70.